

Nonaccidental Trauma in Pediatric Elbow Fractures: When You Should Be Worried

Vaibhav Tadepalli, MD,* Jacob D. Schultz, MD,* Andrew B. Rees, MD,*
Lucas C. Wollenman, MD,* Craig R. Louer, MD,†‡ Nathaniel L. Lempert, MD,†‡
Stephanie N. Moore-Lotridge, PhD,†‡§ and Jonathan G. Schoenecker, MD, PhD†‡§¶||#

Background: Nonaccidental trauma (NAT) is a rising source of morbidity and mortality in the pediatric population. Fractures are often the first cause for presentation to health care providers in the case of NAT but can be misidentified as accidental. Given that elbow fractures are the most common accidental injuries among pediatric patients, they are not traditionally associated with NAT. This study aims to determine the prevalence of NAT among elbow fractures and identify common features in nonaccidental elbow fractures.

Methods: Current Procedural Terminology (CPT) codes were used to retrospectively identify all pediatric (0 to 17) elbow fractures at a single, tertiary children's hospital between 2007 and 2017. Among these, all fractures for which an institutional child abuse evaluation team was consulted were identified. The medical record was then used to determine which of these fractures were due to NAT. Standard injury radiographs of all victims of NAT as well as all patients under 1 year of age were blinded and radiographically evaluated for fracture type by a pediatric orthopaedic surgeon.

Results: The prevalence of nonaccidental elbow fractures across the 10-year study period was 0.4% (N=18). However, the prevalence of nonaccidental elbow fractures in those patients below 1 year of age was markedly higher at 30.3% (10/33). Among all elbow fractures in patients below 1 year of age, supracondylar humerus fractures were the most common fracture type (19/33, 57.6%), yet transphyseal fractures (6/33, 18.1%) were most commonly the result of NAT (5/6, 83.3%). In children over 1 year of age, fracture type was not an indicator of NAT.

Conclusions: The vast majority of pediatric elbow fractures (99.6%) are accidental. However, certain factors, namely age below 1 year and transphyseal fractures increase the likelihood that these fractures may be a result of NAT.

Level of Evidence: Level IV: retrospective case series.

Key Words: nonaccidental trauma, pediatric elbow fractures, transphyseal elbow fractures, elbow, trauma

(*J Pediatr Orthop* 2022;42:e601–e606)

From the *School of Medicine; ||Department of Pharmacology, Vanderbilt University; †Division of Pediatric Orthopaedics, Monroe Carell Jr. Children's Hospital at Vanderbilt; ‡Department of Orthopaedics; ¶Department of Pediatrics; #Department of Pathology, Microbiology, and Immunology; and §Center for Bone Biology, Vanderbilt University Medical Center, Nashville, TN.

Funding for this study was supported by the Caitlin Lovejoy Fund, the Vanderbilt University Medical Center Department of Orthopaedics, and the Vanderbilt School of Medicine Research Immersion program. Creation of the retrospective database utilized in this study was supported by CTSA award no. UL1 TR002243 from the National Center for Advancing Translational Sciences. Its contents are solely the responsibility of the authors and do not necessarily represent official views of the National Center for Advancing Translational Sciences or the National Institutes of Health.

J.G.S. receives research funding from the National Institutes of Health, the Department of Defense, PXE international, and OrthoPediatrics, and receives research support from IONIS Pharmaceuticals. S.N.M.-L. receives research funding from the American Society of Bone and Mineral Research. The remaining authors declare no conflicts of interest.

Reprints: Jonathan G. Schoenecker, MD, PhD, Department of Pediatric Orthopaedics, Monroe Carell Jr. Children's Hospital at Vanderbilt, 2200 Children's Way, Nashville, TN 37232. E-mail: jon.schoenecker@vumc.org. Supplemental Digital Content is available for this article. Direct URL citations appear in the printed text and are provided in the HTML and PDF versions of this article on the journal's website, www.pedorthopaedics.com.

Copyright © 2022 Wolters Kluwer Health, Inc. All rights reserved.
DOI: 10.1097/BPO.0000000000002145

Nonaccidental trauma (NAT) continues to be a significant source of morbidity and mortality in children, with over 4 million instances of abuse and over 1770 abuse-related deaths in 2018 alone in the United States.¹ While tracking the prevalence and trends in NAT can be challenging, various studies have suggested that both the number of cases reviews by child protective services and the incidence of NAT continue to increase in recent years.^{1–3}

While various physical signs can indicate NAT in a child,⁴ such as bruising, burns, or ocular manifestations, fractures are oftentimes the sentinel injury causing presentation to health care providers.⁵ In children, certain fracture locations, such as the femur, posterior rib, or humeral shaft, are classically associated with NAT.^{6,7} Despite the emphasis placed on reporting fractures suspicious for NAT, cases of NAT are still misidentified as accidental in up to one fifth of children.⁸ Furthermore, children were determined to be victims of abuse in ~1 in 6 cases where an investigation was initiated.¹ Thus, there remains an opportunity for medical providers to continue to improve their detection of NAT, in particular following fractures not classically associated with NAT.

Elbow fractures are a common pediatric injury, comprising ~15% of all pediatric fractures.⁹ While

traditionally associated with accidental mechanisms,¹⁰ isolated cases of nonaccidental elbow fractures are reported in the literature and suggest a low incidence of NAT among pediatric elbow fractures.^{11–15} These studies, however, are limited by their sample size and are likely too small to accurately estimate the rate of NAT among pediatric elbow fractures. This study aims to identify the prevalence of NAT among elbow fractures and to identify common features among nonaccidental elbow fractures to aid clinicians in accurately reporting these injuries.

METHODS

Using an institutional Research Derivative with appropriate Institutional Review Board approval (IRB#171899), Current Procedural Terminology (CPT) codes for the treatment of elbow fractures (operative and nonoperative) were used to retrospectively identify pediatric (age 0 to 17) patients diagnosed with and treated for elbow fractures by a pediatric orthopaedic surgeon at a single, large tertiary care center between 2007 and 2017, as previously reported.¹⁶ Humeral shaft fractures without elbow involvement were radiographically identified and excluded.

The electronic medical record (EMR) was used to gather data related to the presentation, management, and evaluation by the Child Protection and Well-Being (CARE) team. At our institution, this CARE team is consulted if there is any clinical suspicion of child abuse. All CARE consultations were reviewed in patients with an elbow injury, and a diagnosis of suspected NAT was made if (1) a diagnosis of suspected NAT was made by a physician who specialized in Child Abuse Pediatrics, (2) a change in custody of the child occurred as a result of the injury, and/or (3) documentation of formal legal proceedings was present related to the injury.

Radiographs of all patients with elbow fractures meeting the above criteria for suspected child abuse were blinded and reviewed for fracture type by a pediatric orthopaedic attending. To compare injury pattern differences between NAT and accidental injuries, radiographs of all patients with elbow fractures under the age of 1 also underwent blinded review for fracture typing by the same physician. The injury patterns as diagnosed by an orthopaedist in patients above 1 year of age were collected from the EMR.

Numerical data were compared using a 2-tailed nonparametric Mann-Whitney test while categorical data were compared using a χ^2 test. Statistical significance was determined at $P < 0.05$. All statistical calculations and figures were generated with GraphPad Prism version 8.0.0 for Windows 10, GraphPad Software, San Diego, CA (<http://www.graphpad.com>).

RESULTS

Across the 10-year study period, a total of 4415 pediatric elbow fractures were evaluated and cared for at this single institution, of which 347 (7.9%) had CARE consultations opened during the initial workup of the

TABLE 1. Patient Demographics

	NAT (N = 18)	Accidental Trauma (N = 4397)	P
Sex, n (%)			
Male	12 (66.7)	2373 (54.0)	0.281
Female	6 (33.3)	2024 (46.0)	
Age, median (range), y	0.8 (0.12–10.4)	6.0 (0.2–16.9)	<0.001

NAT indicates nonaccidental trauma

fracture. Of these 347 patients, 18 (5.2%) patients presenting with an elbow fracture were positively identified as victims of NAT. The demographics of these patients are detailed in Table 1.

Age of Patients Impacted by NAT

Compared with patients experiencing elbow fractures due to accidental trauma, patients identified with elbow fractures secondary to NAT were significantly younger ($P < 0.001$, Table 1). Across all patients, 0.4% (18/4415) of elbow fractures during the study period were the result of NAT. However, among all patients under the age of 1 presenting with an elbow fracture, the rate of NAT was markedly greater at 30% (10/33) of patients. Alternatively, the rate of NAT among patients with elbow fractures between the ages of 1 and 2 and over the age of 2 was ~1% (2/212) and ~0.1% (6/4171), respectively.

Types of Fractures in Patients Under 1 Year of Age

Among patients under the age of 1 ($n = 33$), the most prevalent types of elbow fracture were supracondylar humerus fractures (19/33, 57.6%), metadiaphyseal junction fractures (6/33, 18.2%), and transphyseal fractures (6/33, 18.2%). Importantly, when considering the mechanism of injury, 83.3% (5/6) of transphyseal fractures were found to be due to NAT, accounting for 50% (5/10) of all elbow fractures caused by NAT in children under 1 year of age (Fig. 1). A detailed case example of a patient under the age of 1 with a transphyseal fracture caused by NAT is presented in Figure 2 and Supplemental Video 1 (Supplemental Digital Content 1, <http://links.lww.com/BPO/A473>).

NAT Fracture Characteristics in Patients Above 1 Year of Age

The proportion of NAT among patients with elbow fractures between the ages of 1 and 2 and over the age of 2 was markedly lower at ~1% (2/212) and ~0.1% (6/4171), respectively. In patients 1–2 years of age ($N = 2$), both children sustained supracondylar humerus fractures as a result of the NAT. However, this accounts for only 1.2% (2/173) of all supracondylar humerus fractures in patients 1 to 2 years of age during the study period. In patients over the age of 2 (range: 2.3 to 10.4 y of age) found to have fractures caused by NAT, 5/6 children sustained lateral condyle fractures, while 1 child sustained a supracondylar humerus fractures. Importantly, NAT accounted for only

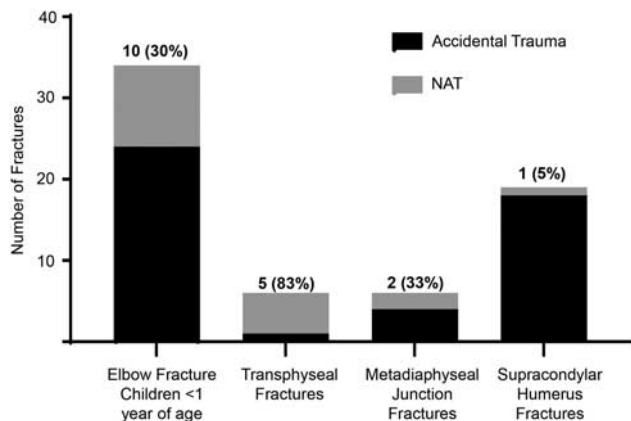


FIGURE 1. Nonaccidental trauma (NAT) in children below 1 year of age with elbow fractures. The leftmost bar indicated all children with elbow fractures below 1 year of age, N = 33, of which 10 (30%) resulted from NAT. The most prevalent fracture types in children below 1 year of age included transphyseal fracture (N = 6), metadiaphyseal junction fractures (N = 6), and supracondylar humerus fractures (N = 19). Percentages in bars indicate the percentage of elbow fractures caused by NAT. Two patients with elbow fractures as a result of NAT were classified as lateral condyle (N = 1) or radial head (N = 1) fractures and not included within the reported fracture types.

0.9% (5/532) of lateral condyle fractures and 0.04% of supracondylar humerus fractures (1/2644) in patients over the age of 2 during the study period.

DISCUSSION

NAT remains a significant source of morbidity and mortality among pediatric patients. Complementing prior clinical reports and small case series, this present study, using a large single-center, pediatric elbow fracture database, a 0.4% incidence of NAT was indicated. While elbow fractures are predominately accidental injuries,¹⁰ this study further confirms that helpful warning signs, such as age below 1 and transphyseal fractures, can aid in the identification of elbow fractures caused by NAT.

Aligning with prior reports, age exerted a tremendous effect on the likelihood that an elbow fracture was the result of NAT, with 30% of elbow fractures in children below 1 year of age being a result of NAT within this study population. This finding indicates that elbow fractures in children below 1 year of age indicate NAT at a similar rate to other associated fracture types in young (under 3 years of age) and nonambulatory children, such as the femur or humeral shaft fractures.^{10,17,18} Thus, while elbow fractures have classically not been a cause for alarm of NAT, this finding illustrates that particularly in children below 1 year of age, providers should exercise similar scrutiny to that when evaluating pediatric femur or humeral shaft fractures.

In addition to age, an important finding from this study was that among elbow fractures in children below 1 year of age, not all fracture types carried the same

association with NAT. Specifically, transphyseal humeral fractures conferred a markedly greater rate of NAT in this patient population (Fig. 2 and Supplemental Video 1, Supplemental Digital Content 1, <http://links.lww.com/BPO/A473>), aligning with prior case reports and small studies.^{9,19–23} Transphyseal fractures are often due to a combination of rotational or shear forces,²³ aligning with injury during twisting or pulling of the extremity in cases of NAT. These fractures are notably difficult to diagnose due to limitations in visualizing the nonossified distal humerus in very young children. Because of this, these fractures are likely often missed as a possible first sign of NAT or as a secondary injury on the skeletal survey. However, given the association identified here and in prior studies, care should be taken to search for this injury among patients below 1 year of age with elbow pain or any child who is the suspected victim of NAT. Physical exam findings such as pain, ecchymosis, and swelling, coupled with careful scrutiny of the elbow film on the skeletal survey will aid clinicians in accurate diagnosis. It is essential to obtain a true anterior-posterior (AP) and lateral radiograph of the elbow as part of the skeletal survey to be able assess the alignment of the capitellar ossification center with the shaft of the radius (AP).²⁴ Where possible, these films should be reviewed by a pediatric radiologist or pediatric orthopaedist for highest sensitivity.

Finally, this study found that in patients over 1 year of age, the rate of NAT resulting in elbow fracture was markedly lower. In addition, the types of fractures experienced aligned with common accidental fracture patterns, including supracondylar humerus and lateral condyle fractures. As such, fracture type in patients over 1 year of age was not an indicator of NAT; thus, physicians must still rely on common indicators that raise the suspicion of NAT.

Common Presentation of Children With NAT-Utility of Prediction Algorithms to Help Guide When a CARE Consultation Should Be Initiated?

Accurate and timely detection of NAT in children is paramount. Upon presentation, signs of suspicious bruising, the presence of burns, or instances of fractures, particularly of ribs or long bones, are considered classical indicators of potential abuse in children.²⁵ In addition, in cases of NAT, the history provided by the caretakers is often inconsistent with the injuries present, and there may likewise be additional evidence of poor care of the child. Furthermore, evaluation of the injuries upon presentation relative to the age and ambulation status of the child can be a helpful indicator of potential abuse, given that the risk of NAT is inversely associated with the age of the child and most confirmed NAT cases occur in children younger than 2 years of age.^{25–27} While each of these above-noted factors can be an indicator for potential abuse, it is important for medical providers to continue to evaluate the case to provide sufficient, but also accurate, reporting for suspected child abuse.

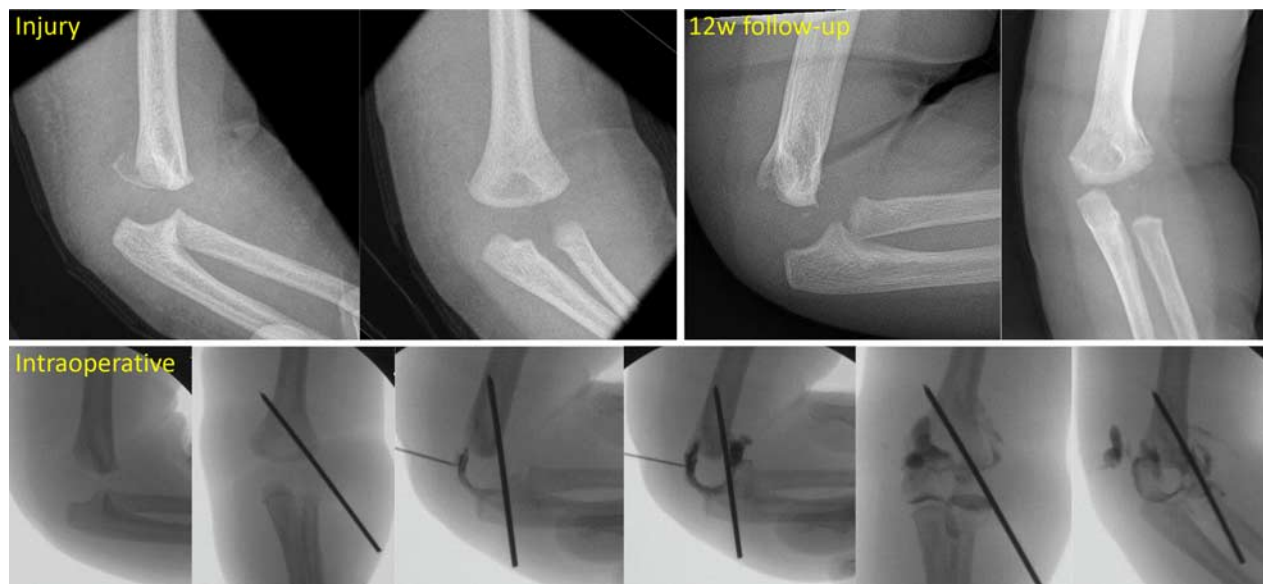

FIGURE 2. Example of a pediatric patient below 1 year of age with a transphyseal fracture resulting from suspected nonaccidental trauma. Radiographic imaging at presentation to the emergency department illustrated a fracture of the left distal humerus, primarily involving the posterior medial aspect with mild displacement and no callus formation. A true lateral view was not able to be obtained. Patient was taken to the OR for a closed reduction and percutaneous pinning. Following a successful closed reduction, a single k-wire was inserted from the lateral side to provide stability where the periosteum was torn. An arthrogram was then performed to verify the reduction (Supplemental Video 1, Supplemental Digital Content 1, <http://links.lww.com/BPO/A473>). Percutaneous pin were removed at 23 days following surgery. At 12-weeks following surgery marked healing of the transphyseal fracture was observed with near-anatomic alignment and callus remodeling observed.

To assist with detecting and distinguishing cases of abuse in children, multiple studies have focused on developing care and prediction algorithms.^{25,28} In 2021, the Western Trauma Association and Pediatric Trauma Society published a joint recommendation on a clinical decision algorithm for the management of children with concern for physical abuse.²⁸ This publication provides an overview of the key “red flags” when evaluating a child for suspected abuse, and a comprehensive overview of the recommended clinical workflow. Complementing this work, a recent large-scale study assessing predictors of NAT in children with fractures recorded as part of the national inpatient database, reported that younger age, the presence of intracranial injury, concomitant rib fracture, and concomitant burns were all positive predictors of NAT in children with fractures.²⁹ Similarly, work by Baldwin and colleagues found that in children with femur fractures, risk factors that aided in predicting NAT included age below 18 months, physical or radiographic evidence of a prior injury, or an inconsistent or suspicious history from the caregivers. Through retrospective analysis of 70 children with nonaccidental femur fractures and 139 children with accidental femur fractures, they found that children with no risk factors had a 4% chance, children with one risk factor had a 29% chance, children with two risk factors had an 87% chance, and children with all 3 risk factors had a 92% chance of their femur fracture being a result of NAT.³⁰ Furthermore, a similar study by Pandya and colleagues found that similar variables independently predicted NAT in children with humerus

fractures.³⁰ Taken together, findings from these studies can help aid physicians and medical providers in detecting, distinguishing, and responding to cases of NAT.

Identifying Transphyseal Supracondylar Humerus Fracture in Young Children

As mentioned previously, transphyseal supracondylar humerus fractures are highly associated with NAT in very young patients.³¹ As such, in those patients for whom concern for NAT has already been raised due to the presence of previously mentioned warning signs or in those patients younger than 1 year with significant elbow pain, thorough investigation of the elbow is vital to accurate diagnosis of transphyseal fractures. Radiographs are often unreliable in this injury pattern secondary to their inability to visualize the nonossified distal humeral epiphysis. However, malalignment of either the ulnohumeral or radiocapitellar joint on AP and lateral radiographs can be concerning findings for transphyseal fractures. Furthermore, with adequate analgesia or procedural sedation, an anterior to posterior force can be applied to the elbow and show displacement of the ulnohumeral joint with respect to the humeral shaft, with or without an arthrogram. This can confirm fracture through the distal humeral physis. Upon diagnosis, at the study institution, these fractures are typically managed operatively with closed reduction and percutaneous pin fixation. The number of pins and construct used is determined by performing intraoperative stress testing including flexion, extensions, varus, valgus, and internal/

external-rotational maneuvers.³² The minimum number of pins that is sufficient to prevent failure of stress testing in any plane is accepted. Lateral-entry pinning is preferred, unless it is found to be insufficient at preventing failure of internal-rotational stress testing, and if so a medial-entry pin is added to create a cross-pinning construct.³³

Family Risk Factors Associated With NAT

Across the last 2 decades, numerous studies have investigated the effects of race and socioeconomic status on the rate of abuse in children. While a variable consensus has been drawn regarding the rates of abuse relative to race or socioeconomic status,³⁴ numerous societal factors have been found to influence the rate of NAT. Specifically, lack of community support available to parents, prior history of alcohol/drug abuse or violence, engagement in criminal activity, life stressors, or an impaired psychological state have each been found to lead to an increased likelihood of NAT. Given that families from all racial and socioeconomic backgrounds can be influenced by these factors, it is important for providers to continue to work towards limiting racial and socioeconomic bias when evaluating NAT.^{28,35,36}

Limitations

This study, like many other retrospective studies assessing rates of NAT, is limited by the fact that outcomes from DCS investigations are many times not definitive. As such, studies in this field of research must rely on proxies and documentation available to determine the primary endpoint and presence of NAT.^{8,17,37,38} In addition to the possibility that cases of NAT were missed upon presentation,⁸ it is also likewise possible that cases were not identified retrospectively in this study due to insufficient documentation by the provider. The authors believe that the criteria outlined to classify patients as victims of NAT within this study are of sufficient quality to identify the greatest number of cases possible given these limitations. Through assessing multiple years of records from patients experiencing all severities of elbow fractures derived from a large single-center pediatric elbow fracture database, this study aimed to limit ascertainment bias to provide an accurate incidence of NAT within this population. In addition, all cases were discovered through CPT search for operative or nonoperative management of elbow fractures. Although CPT coding was the standard billing practice at the single center for these injuries during the time of investigation, it is possible that some cases were overlooked if they were coded only through E&M without an associated CPT. Despite these limitations, the authors believe this study remains a valuable addition to the literature.

CONCLUSION

Elbow fractures in ambulatory children have a very low likelihood (0.4%) of being caused by NAT. However, the likelihood of transphyseal elbow fractures being caused by NAT climbs in patients below 1 year of age, with rates of NAT comparable to that of the femur or

humeral shaft fractures. Furthermore, transphyseal fractures in children below 1 year of age were associated with a NAT injury mechanism. By understanding the patient and fracture characteristics most frequently associated with NAT, these findings can assist providers in detecting this diagnosis.

ACKNOWLEDGMENTS

The authors would like to thank members of the Division of Pediatric Orthopaedics, Pediatric Emergency Medicine, and the Vanderbilt Child Protection and Well-Being (CARE) team for their care of patients at our institution; this work would not have been possible without their dedication. The creation of this database and the associated analysis has been reviewed by individuals with experience in biostatistics. They also thank their family and friends for their continued support and understanding.

REFERENCES

1. US Department of Health and Human Services, Administration for Children and Families, Administration on Children Youth and Families, Children's Bureau. Child maltreatment 2018. 2020. Available at: <https://www.acf.hhs.gov/cb/report/child-maltreatment2018>.
2. Kovler ML, Ziegfeld S, Ryan LM, et al. Increased proportion of physical child abuse injuries at a level I pediatric trauma center during the Covid-19 pandemic. *Child Abuse Neglect*. 2021;116(pt 2):104756.
3. Thompson LW, Bass KD, Agyei JO, et al. Incidence of nonaccidental head trauma in infants: a call to revisit prevention strategies. *J Neurosurg*. 2019;24:689–696.
4. Pressel DM. Evaluation of physical abuse in children. *Am Fam Physician*. 2000;61:3057–3064.
5. Christian CW. The evaluation of suspected child physical abuse. *Pediatrics*. 2015;135:e1337–e1354.
6. Berthold O, Frericks B, John T, et al. Abuse as a cause of childhood fractures. *Dtsch Arztebl Int*. 2018;115:769–775.
7. Barsness KA, Cha ES, Bensard DD, et al. The positive predictive value of rib fractures as an indicator of nonaccidental trauma in children. *J Trauma*. 2003;54:1107–1110.
8. Ravichandiran N, Schuh S, Bejuk M, et al. Delayed identification of pediatric abuse-related fractures. *Pediatrics*. 2010;125:60–66.
9. Shrader MW. Pediatric supracondylar fractures and pediatric physeal elbow fractures. *Orthop Clin North Am*. 2008;39:163–171; v.
10. Kemp AM, Dunstan F, Harrison S, et al. Patterns of skeletal fractures in child abuse: systematic review. *BMJ*. 2008;337:a1518.
11. Farnsworth CL, Silva PD, Mubarak SJ. Etiology of supracondylar humerus fractures. *J Pediatr Orthop*. 1998;18:38–42.
12. Ross AH, Abel SM. *The Juvenile Skeleton in Forensic Abuse Investigations*, 1st ed. New York, NY: Humana Press; 2011.
13. Levin H, Sangha G, Carey TP, et al. Fracture and nonaccidental injury: a case report of a lateral condylar fracture in a 13 month old. *Pediatr Emerg Care*. 2016;32:865–867.
14. Rosado N, Ryznar E, Flaherty EG. Understanding humerus fractures in young children: abuse or not abuse? *Child Abuse Negl*. 2017;73:1–7.
15. Strait RT, Siegel RM, Shapiro RA. Humeral fractures without obvious etiologies in children less than 3 years of age: when is it abuse? *Pediatrics*. 1995;96(pt 1):667–671.
16. Schultz JD, Rees AB, Wollenman LC, et al. Factors that drive annual variation in pediatric elbow fracture occurrence, severity, and resource utilization. *J Pediatr Orthop*. 2021;41:e755–e762.
17. Leaman LA, Hennrikus WL, Bresnahan JJ. Identifying non-accidental fractures in children aged <2 years. *J Child Orthop*. 2016;10:335–341.
18. Wood JN, Fakeye O, Mondestin V, et al. Prevalence of abuse among young children with femur fractures: a systematic review. *BMC Pediatr*. 2014;14:169.
19. Sen RK, Bedi GS, Nagi ON. Fracture epiphyseal separation of the distal humerus. *Australas Radiol*. 1998;42:271–274.

20. Gilbert SR, Conklin MJ. Presentation of distal humerus physal separation. *Pediatr Emerg Care*. 2007;23:816–819.
21. Supakul N, Hicks RA, Caltoum CB, et al. Distal humeral epiphyseal separation in young children: an often-missed fracture-radiographic signs and ultrasound confirmatory diagnosis. *AJR Am J Roentgenol*. 2015;204:W192–W198.
22. Nimkin K, Kleinman PK, Teeger S, et al. Distal humeral physal injuries in child abuse: MR imaging and ultrasonography findings. *Pediatr Radiol*. 1995;25:562–565.
23. DeLee JC, Wilkins KE, Rogers LF, et al. Fracture-separation of the distal humeral epiphysis. *J Bone Joint Surg Am*. 1980;62:46–51.
24. Abzug JM, Ho CA, Ritzman TF, et al. Transphyseal fracture of the distal humerus. *JAAOS*. 2016;24:e39–e44.
25. Paul AR, Adamo MA. Non-accidental trauma in pediatric patients: a review of epidemiology, pathophysiology, diagnosis and treatment. *Transl Pediatr*. 2014;3:195–207.
26. Baldwin JA, Oliver JE. Epidemiology and family characteristics of severely-abused children. *Br J Prev Soc Med*. 1975;29:205–221.
27. Agran PF, Anderson C, Winn D, et al. Rates of pediatric injuries by 3-month intervals for children 0 to 3 years of age. *Pediatrics*. 2003;111(pt 1):e683–e692.
28. Rosen NG, Escobar MAJ, Brown CV, et al. Child physical abuse trauma evaluation and management: a Western Trauma Association and Pediatric Trauma Society critical decisions algorithm. *J Trauma Acute Care Surg*. 2021;90:641–651.
29. Zhao C, Starke M, Tompson JD, et al. Predictors for nonaccidental trauma in a child with a fracture—a National Inpatient Database Study. *JAAOS*. 2020;28:e164–e171.
30. Baldwin K, Pandya NK, Wolfgruber H, et al. Femur fractures in the pediatric population: abuse or accidental trauma? *Clin Orthop Relat Res*. 2011;469:798–804.
31. Hariharan AR, Ho C, Bauer A, et al. Transphyseal humeral separations: what can we learn? A retrospective, multicenter review of surgically treated patients over a 25-year period. *J Pediatr Orthop*. 2020;40:e424–e429.
32. Rees AB, Schultz JD, Wollenman LC, et al. Internal rotation stress test reduces cross-pinning and improves outcomes in displaced pediatric supracondylar humeral fractures. *JB JS Open Access*. 2021;6:e21.00014.
33. Rees AB, Schultz JD, Wollenman LC, et al. A mini-open approach to medial pinning in pediatric supracondylar humeral fractures may be safer than previously thought. *J Bone Joint Surg Am*. 2022;104:33–40.
34. Rosenfeld EH, Johnson B, Wesson DE, et al. Understanding non-accidental trauma in the United States: a national trauma databank study. *J Pediatr Surg*. 2020;55:693–697.
35. Hymel KP, Laskey AL, Crowell KR, et al. Racial and ethnic disparities and bias in the evaluation and reporting of abusive head trauma. *J Pediatr*. 2018;198:137.e1–43.e1.
36. Voss A. Bias in the workup for non-accidental trauma (NAT) in patients under age 1 brought to the emergency department for a reported fall that may be suspect for child abuse. 2020. Available at: <https://etd.library.emory.edu/concern/etds/sb3979399?locale=it>Masters thesis.
37. Picini M, Gonçalves JRR, Bringhenti T, et al. Evaluation of suspected physical abuse in children: a 500-case study. *Rev Bras Ortop*. 2017;52:284–290.
38. Leventhal JM, Thomas SA, Rosenfield NS, et al. Fractures in young children. Distinguishing child abuse from unintentional injuries. *Am J Dis Child*. 1993;147:87–92.